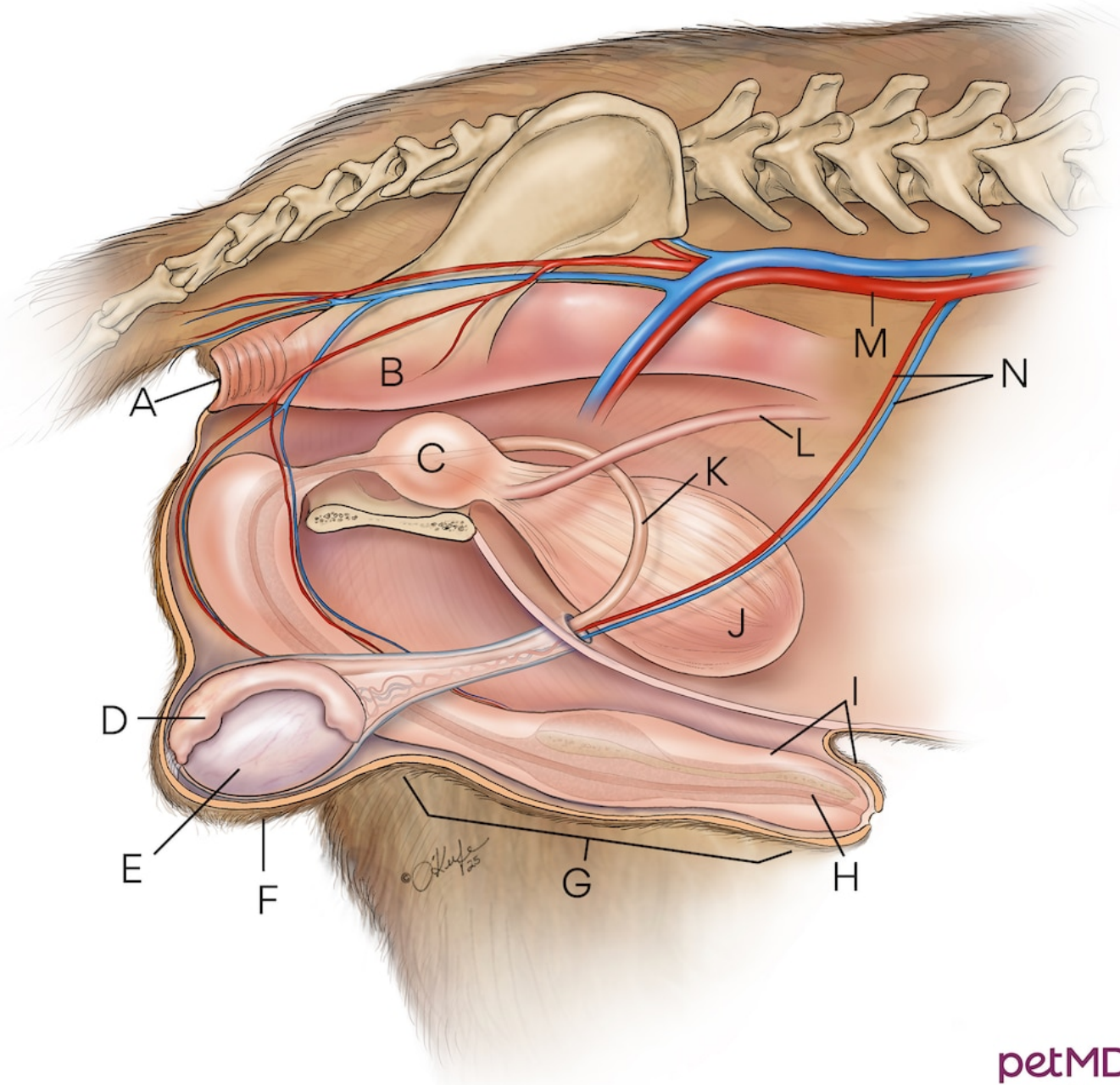


Anatomy of the Male Reproductive System in Dogs



petMD
by chewy

- A.** Anus **B.** Colon **C.** Prostate **D.** Epididymis **E.** Testicle
F. Scrotum **G.** Penis **H.** Urethra **I.** Prepuce **J.** Bladder
K. Vas deferens (spermatic duct) **L.** Ureter **M.** Aorta
N. Testicular vessels