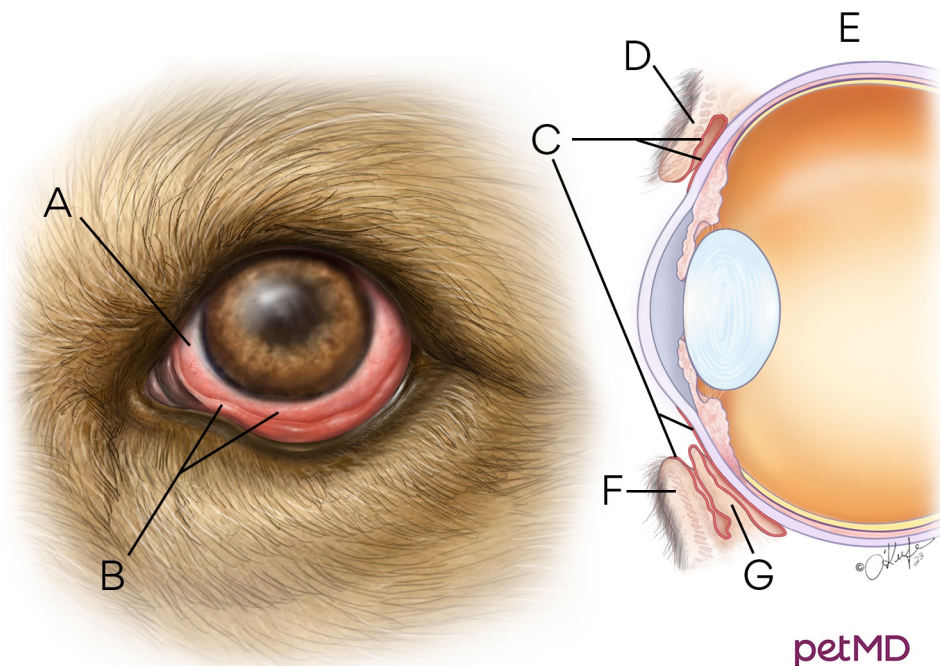


## Conjunctival Hyperemia



petMD  
by chewy

- A.** Sclera    **B.** Redness and swelling of vessels within the conjunctival tissue    **C.** Conjunctival tissue covers the sclera and inside of eyelid    **D.** Upper eyelid  
**E.** Cross section of eye    **F.** Lower eyelid  
**G.** Third eyelid