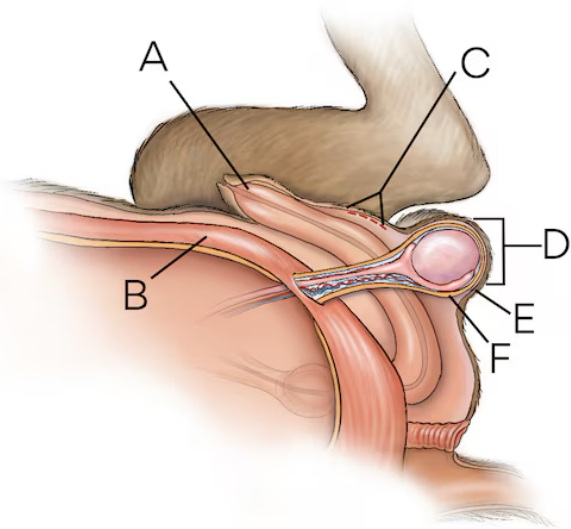
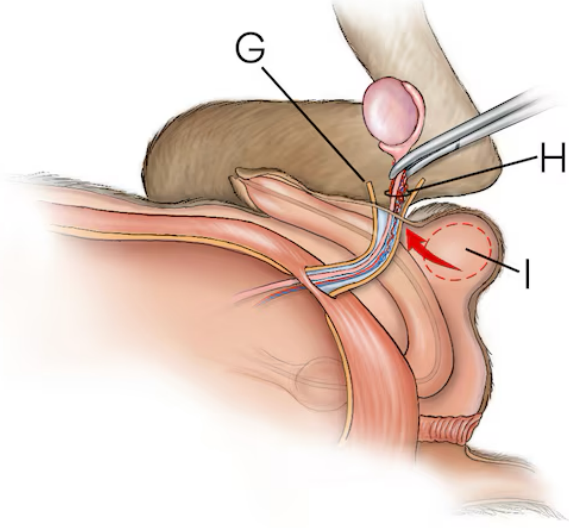


Dog Neutering

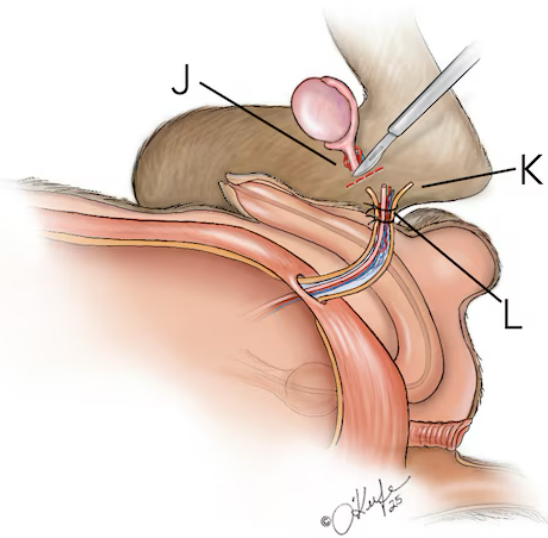
Pre-scrotal neuter



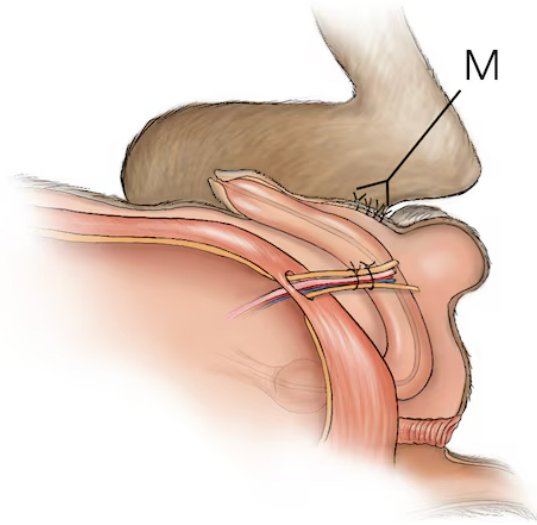
1. Incise skin in front of scrotal sac



2. Exteriorize testicles



3. Ligate vessels



4. Close incision

petMD
by chewy

A. Penis **B.** Abdominal wall **C.** Incision site **D.** Testicle in scrotal sac
E. Scrotum **F.** Vaginal tunic **G.** Vaginal tunic incised and testicle exposed **H.** Spermatic cord **I.** Testicle is pushed through incision
J. Remove testicle **K.** Spermatic cord cut above ties **L.** Ligatures placed **M.** Skin sutures