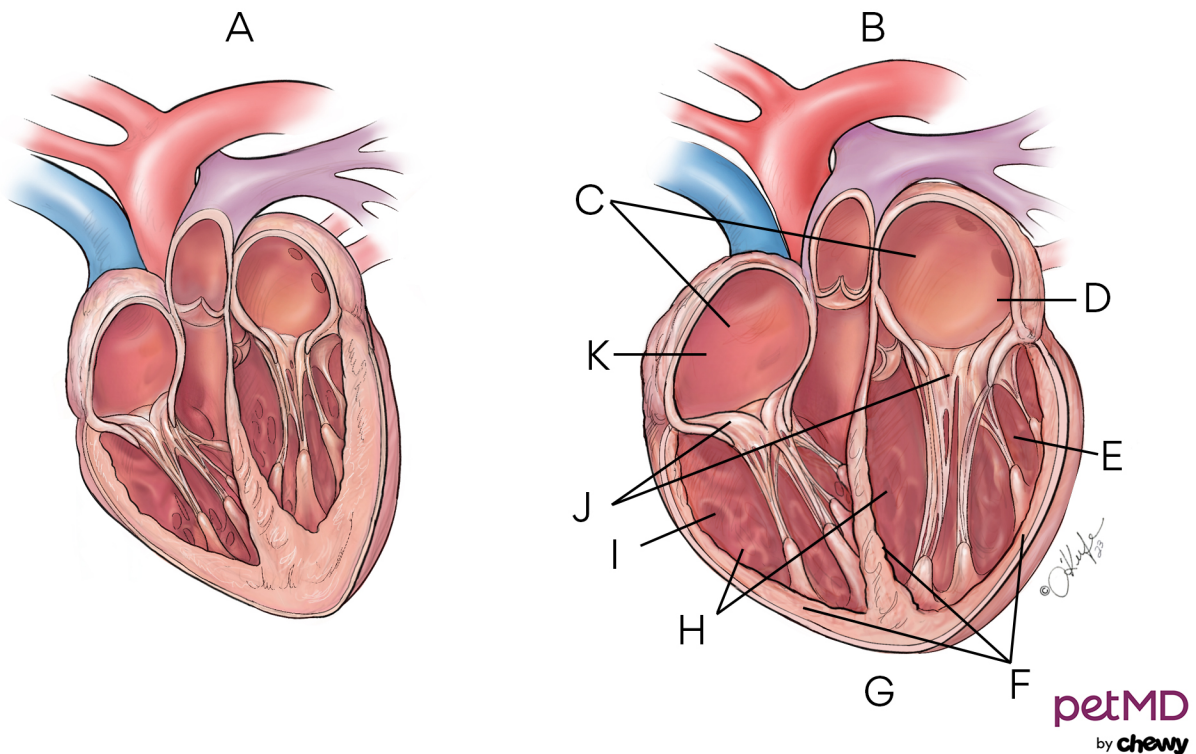


Enlarged Heart (Dilated Cardiomyopathy) in Dogs



A. Normal heart **B.** Dilated cardiomyopathy **C.** Enlarged atria **D.** Left atrium **E.** Left ventricle **F.** Thinning of ventricular walls **G.** Atria and ventricles enlarged due to stretching and thinning of heart muscle **H.** Enlarged ventricles **I.** Right ventricle **J.** Heart valves unable to close completely **K.** Right atrium