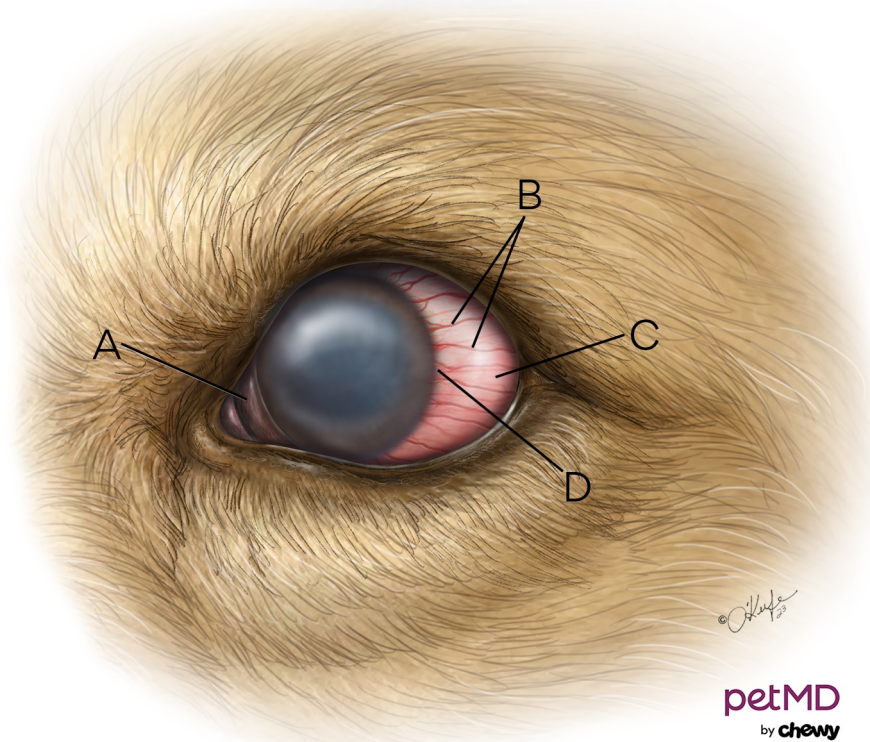


Episcleral Injection



A. Third eyelid **B.** Enlarged (congested) vessels appear more straight and run 90 degrees to the limbus **C.** Sclera **D.** Limbus