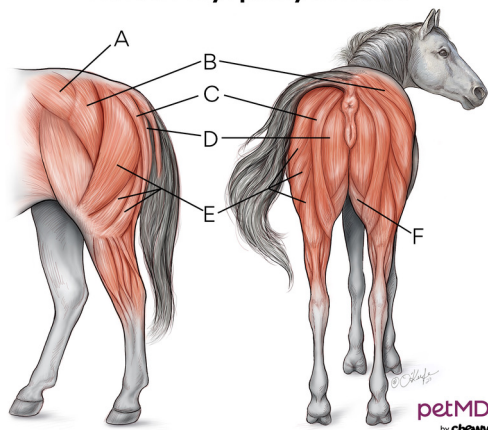


Fibrotic Myopathy in Horse



- A. Middle gluteal
- B. Superficial gluteal
- C. Semitendinosus
- D. Semimembranosus
- E. Biceps femoris
- F. Gracilis