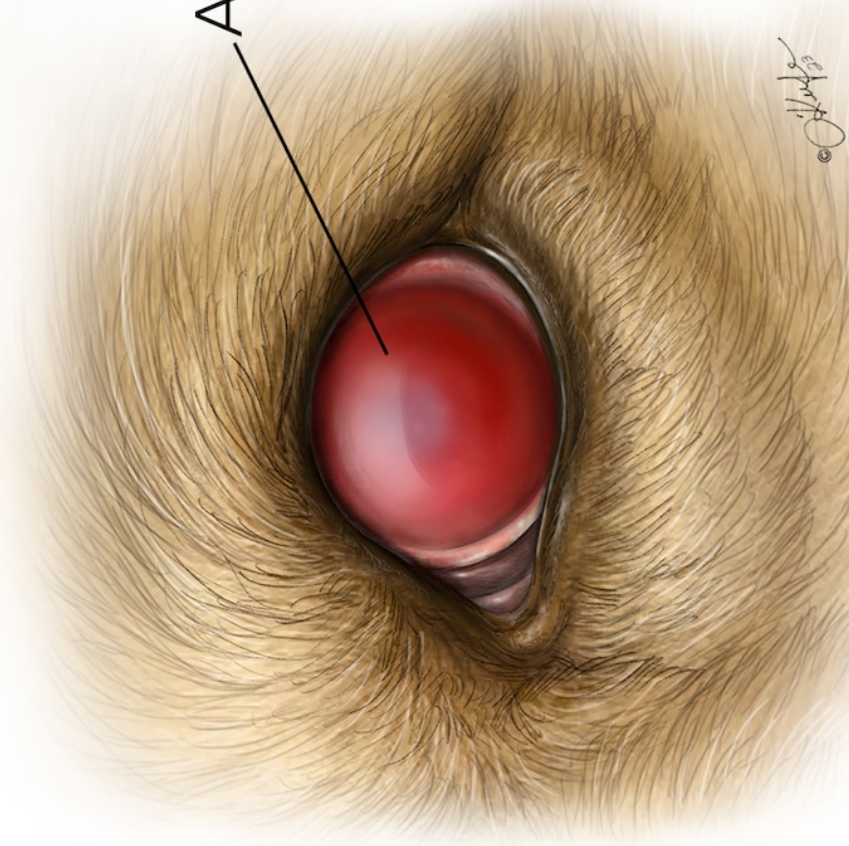
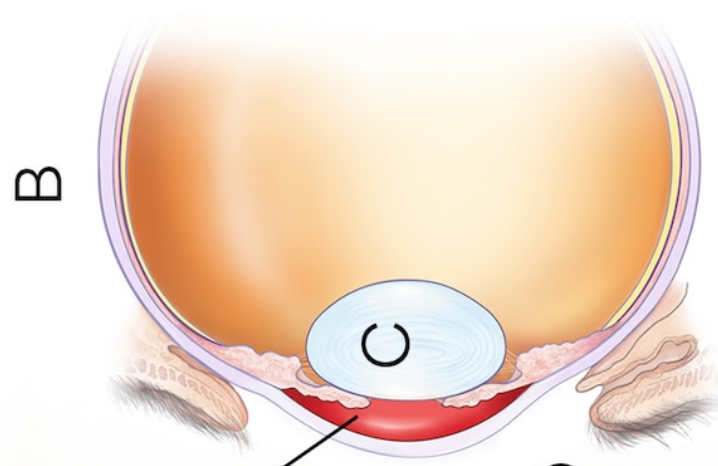


HypHEMA



petMD
by chewy

A. Pooling of blood filling anterior chamber of eye **B.** Cross section of eye **C.** Lens
D. Cornea

© 2013