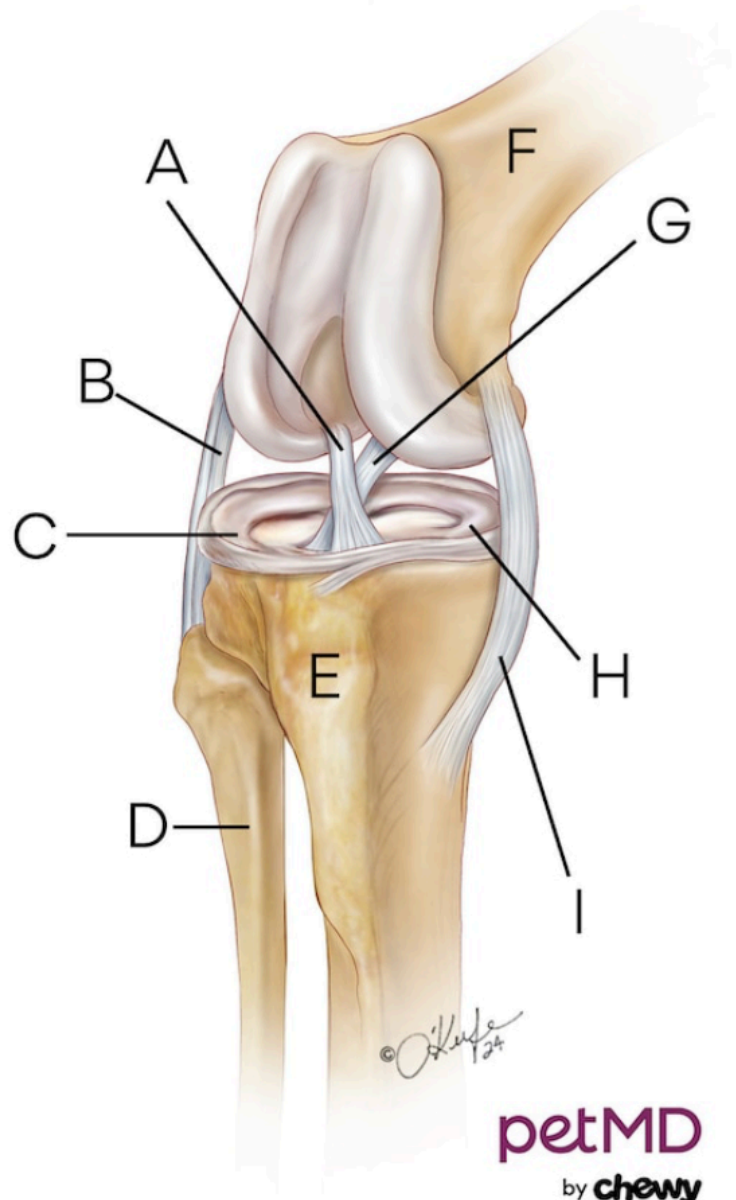
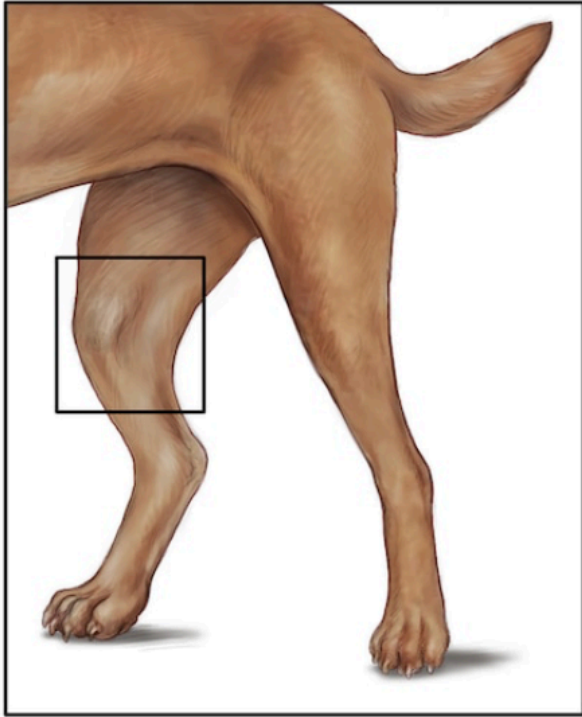


Intact Cranial Cruciate Ligament



petMD
by chewy

- A.** Cranial cruciate ligament (ACL)
- B.** Lateral collateral ligament
- C.** Lateral meniscus
- D.** Fibula
- E.** Tibia
- F.** Femur
- G.** Caudal cruciate ligament (ACL)
- H.** Medial meniscus
- I.** Medial collateral ligament