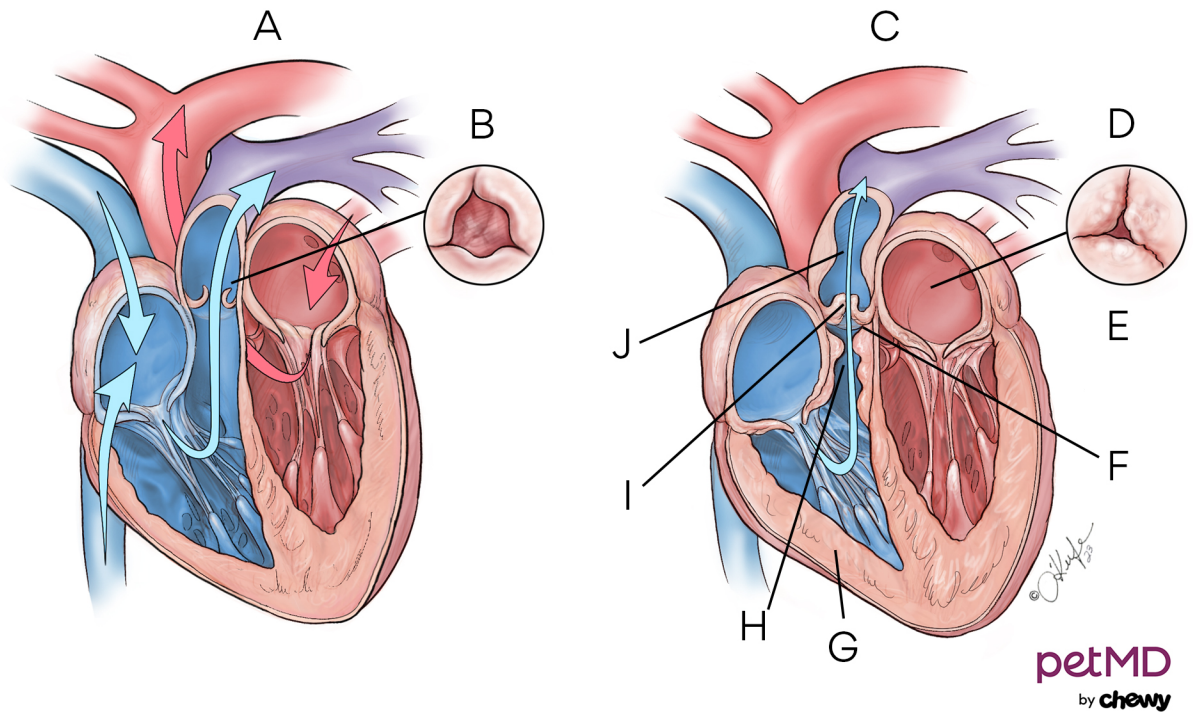


## Pulmonic Stenosis in Dogs



**A.** Normal heart    **B.** Top view of valve open    **C.** Pulmonic stenosis    **D.** Top view of valve open    **E.** Valve is narrowed and thickened and unable to open completely    **F.** Harder to pump blood across narrowed obstructed valve    **G.** Right ventricle becomes thickened    **H.** Subvalvular- thickening of muscle below valve    **I.** Valvular- narrow opening leaflets of valve are fused together and thickened    **J.** Supravalvular- narrowing of pulmonary artery above valve