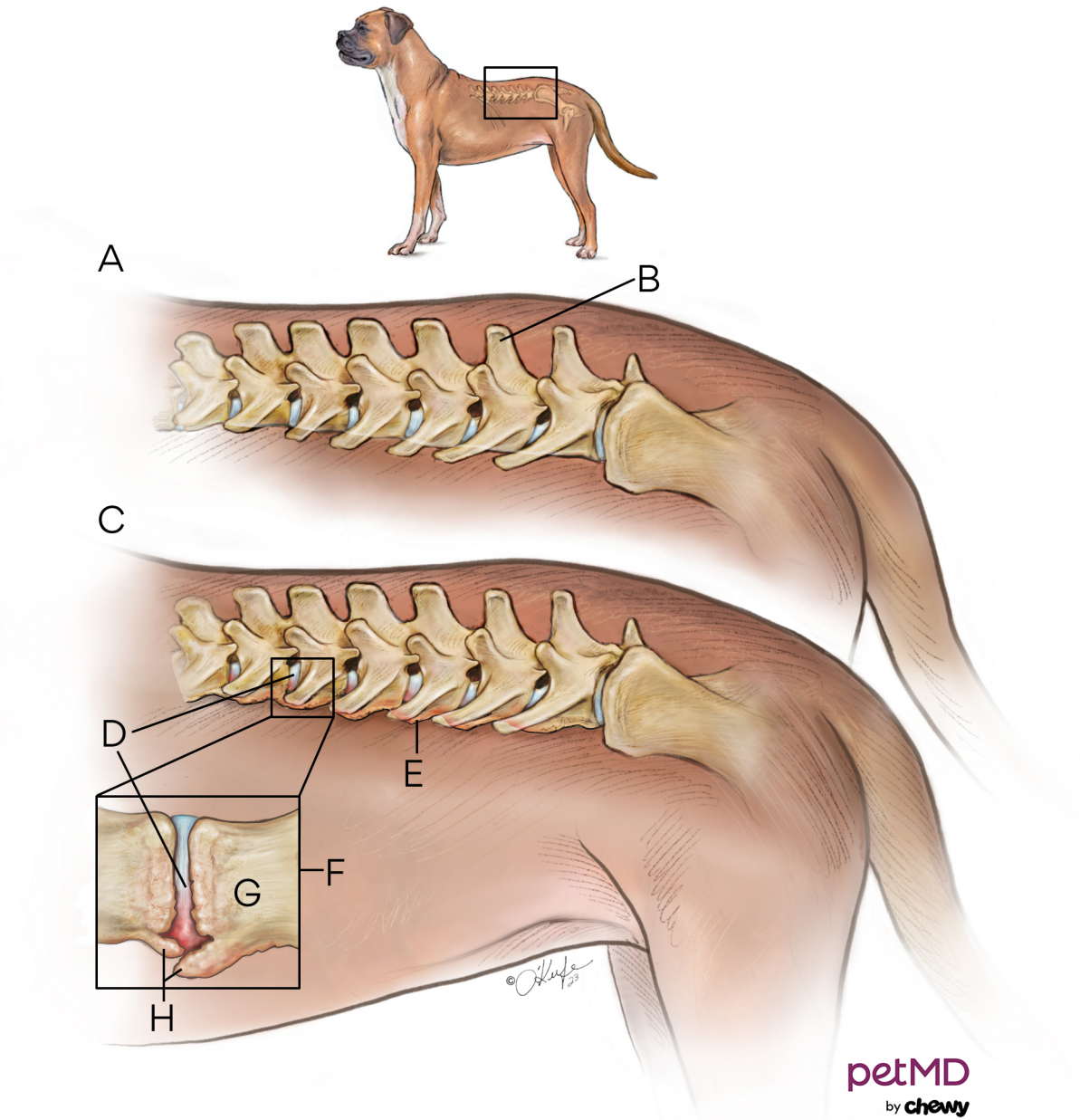


Spondylosis Deformans in Dogs



- A.** Normal **B.** Lumbar vertebrae **C.** Spondylosis
D. Intervertebral disc **E.** Bone spurs or osteophytes
at endplates of vertebral body **F.** Intervertebral disc
degenerates and bone spurs develop to reestablish
stability to weakened joint **G.** Endplate **H.** Bone spurs