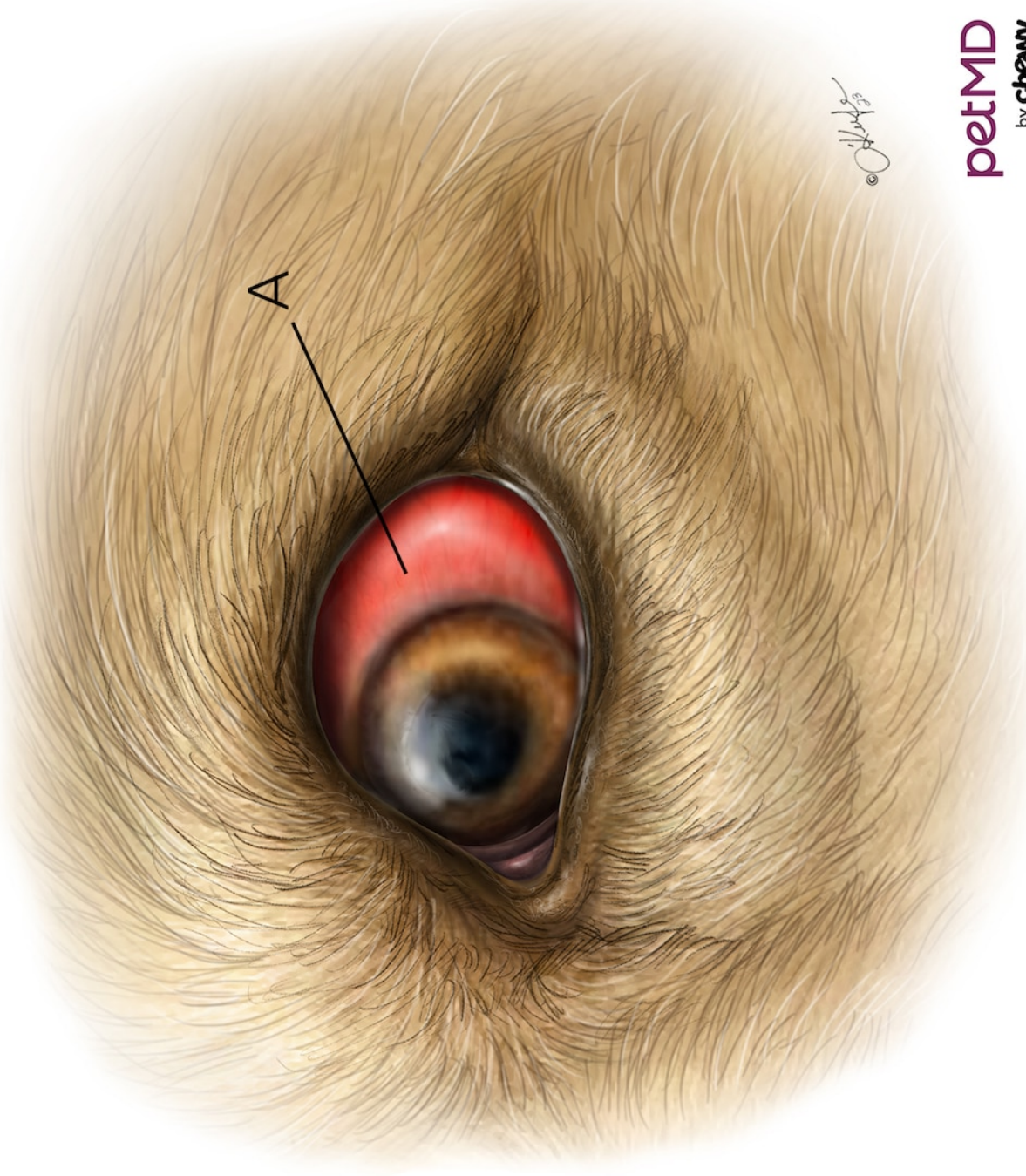


Subconjunctival Hemorrhage



© *Hand-drawn*

petMD
by **chewy**

A. Diffuse redness in white part (sclera) of eye