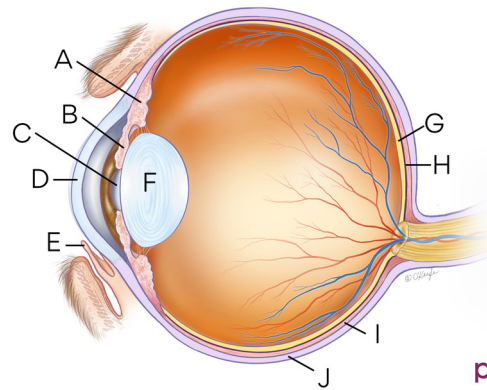


Uveitis in Cats



- A.** Ciliary body **B.** Iris **C.** Pupil **D.** Cornea
E. 3rd eyelid **F.** Lens **G.** Retina **H.** Tapetum
I. Choroid **J.** Sclera

petMD
by chewy