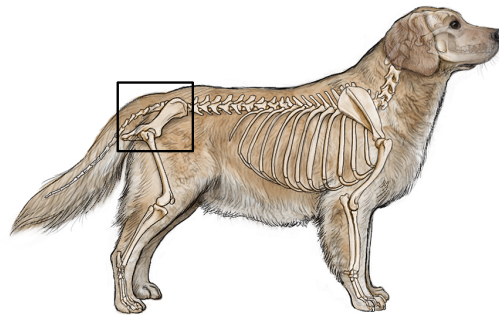
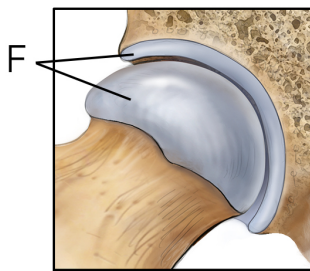
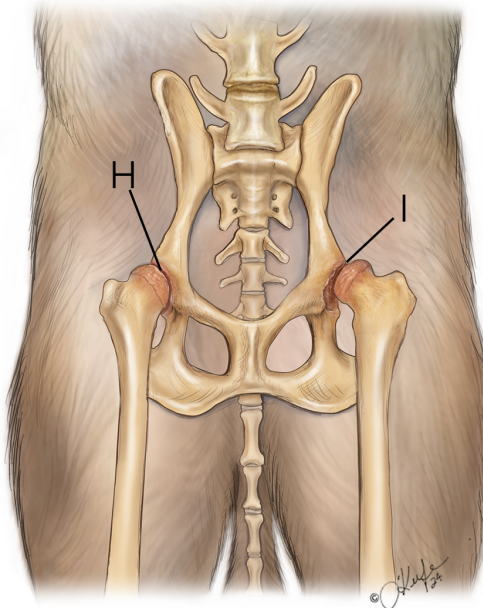
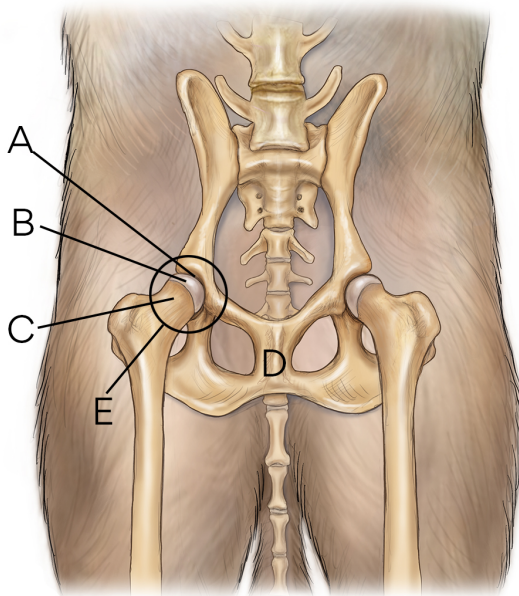


Hip Dysplasia in Dogs

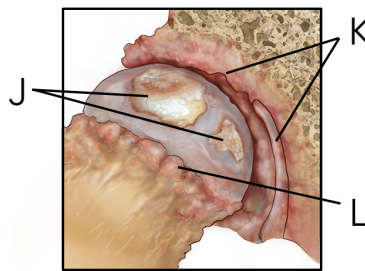


Normal Dog Hips

Dog With Hip Dysplasia



G



M

petMD
by chewy

- A.** Acetabulum (socket) of hip (pelvis)
- B.** Femoral head (ball)
- C.** Femoral neck
- D.** Pelvis
- E.** Ball and socket joint
- F.** Cartilage
- G.** Normal joint

- H.** Shallow hip socket
- I.** Ball and socket do not fit or develop properly
- J.** Erosion of cartilage exposes bone
- K.** Loss of cartilage
- L.** Osteophytes (bone spurs)
- M.** Deterioration of joint leads to osteoarthritis