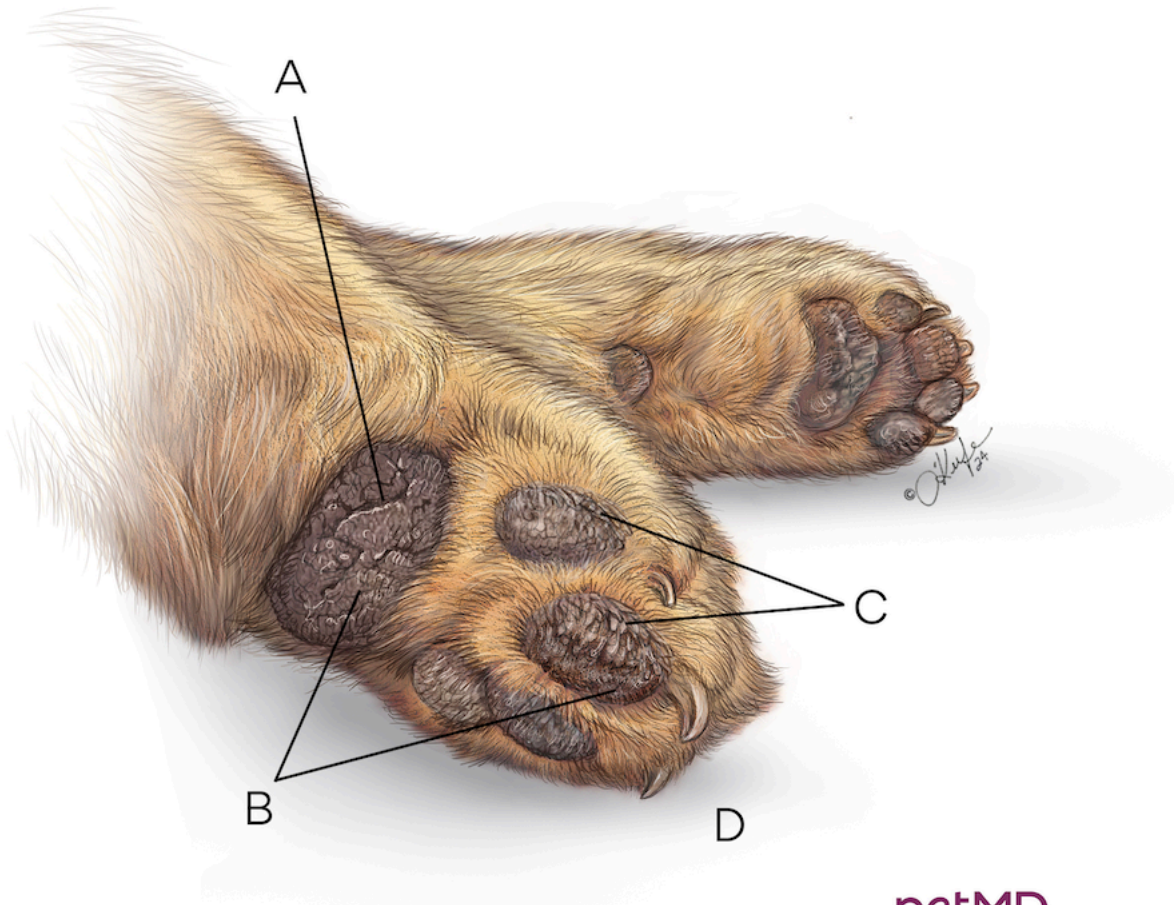


Hyperkeratosis in Dogs



petMD
by chewy

- A.** Protective outer layer of pad may crack or erode and become susceptible to infection
- B.** Rough, thickened, dry, crusty areas on paw pads
- C.** Thick feathered skin overgrowth on edges of pads
- D.** Skin becomes harder and thicker from excess keratin production