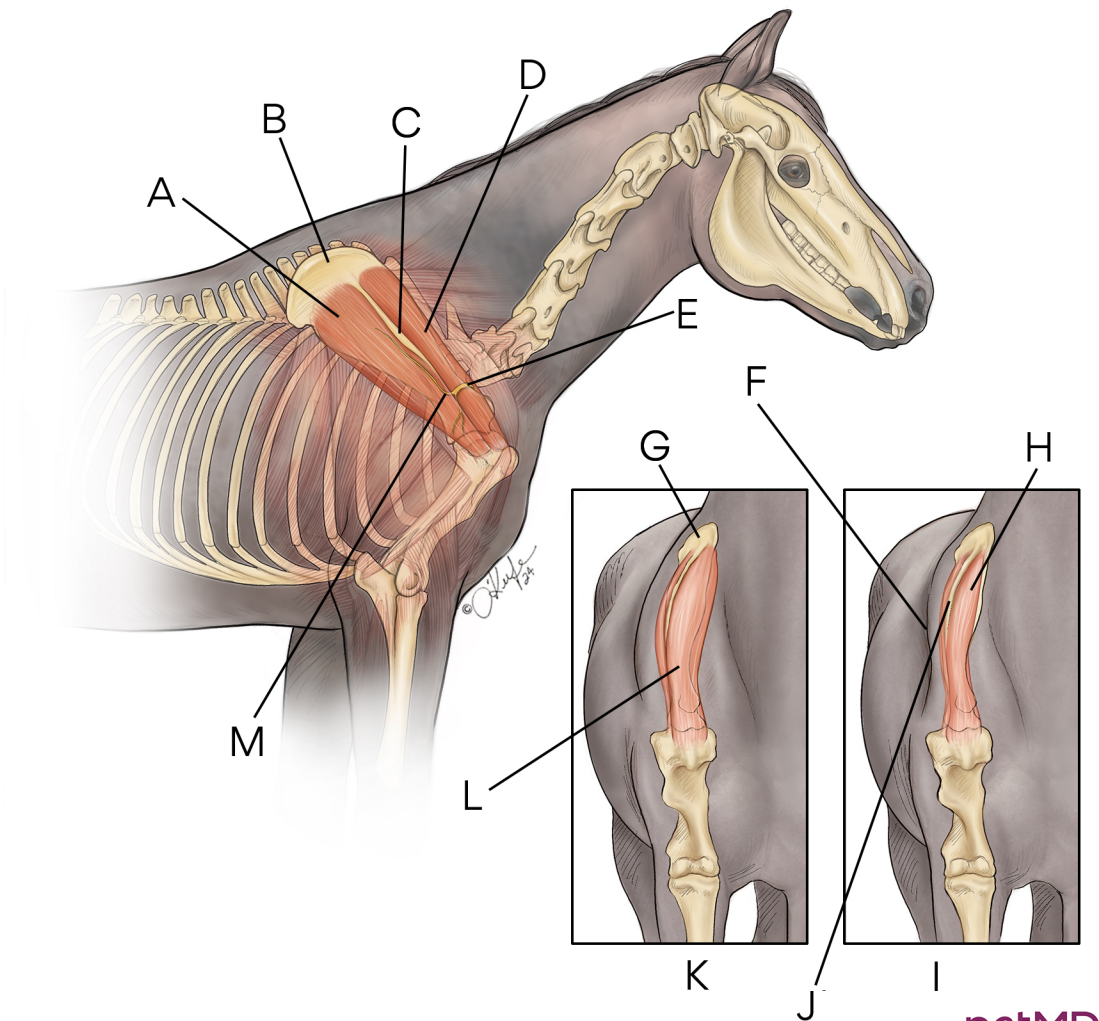


Sweeney Shoulder in Horses



petMD
by chewy

A. Infraspinatus muscle **B.** Scapula **C.** Spine of scapula **D.** Supraspinatus muscle **E.** Trauma to suprascapular nerve causes muscles of shoulder to become compromised **F.** Hollowing around spine of scapula **G.** Scapula **H.** Atrophy of shoulder muscles **I.** Muscle atrophy **J.** Scapular spine becomes prominent due to muscle wasting **K.** Normal muscle **L.** Supraspinatus muscle **M.** Suprascapular nerve provides innervation to infraspinatus and supraspinatus muscles