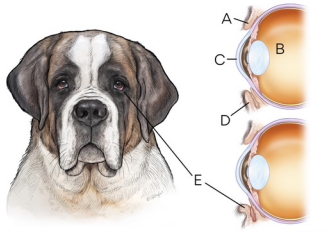


Ectropion in Dogs



petMD
by cheery

- A. Upper eyelid
- B. Normal eye
- C. Cornea
- D. Lower eyelid
- E. Ectropion (rolled outward eyelid)