

Cracked Paws in Dogs

Dog Paw Skin Cell Layers

Crack in paw pad

Keratinocyte

Langerhans cell

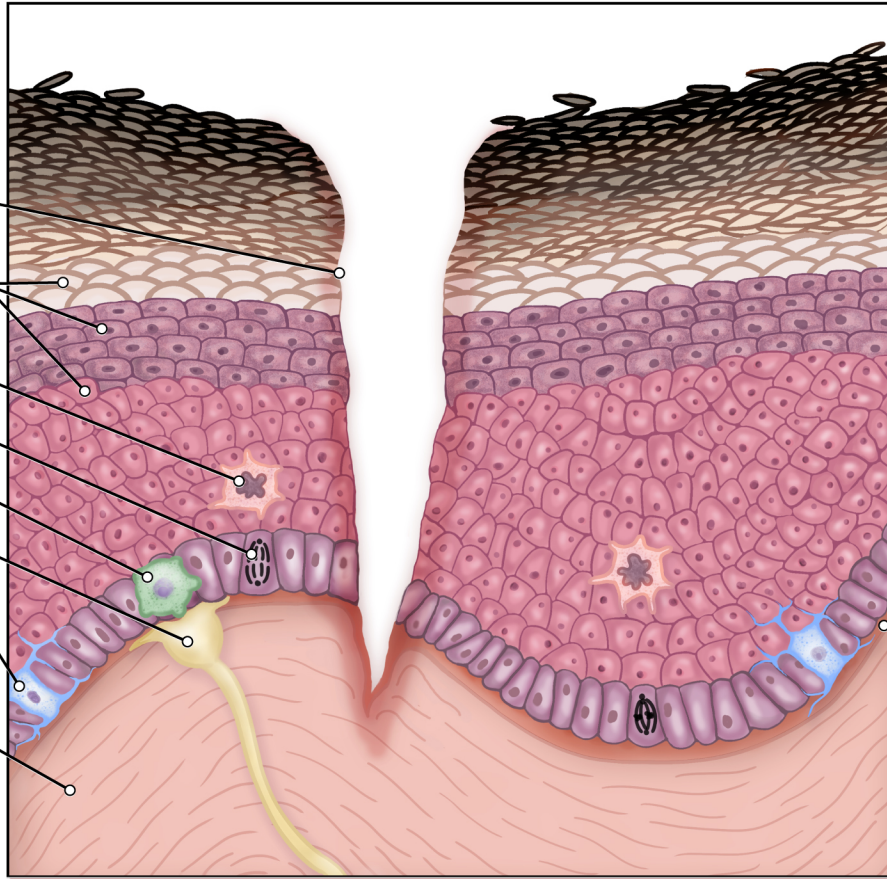
Dividing basal cell

Merkel cell

Sensory neuron

Melanocyte

Connective tissue



Stratum corneum

Stratum lucidum

Stratum granulosum

Stratum spinosum

Stratum basale

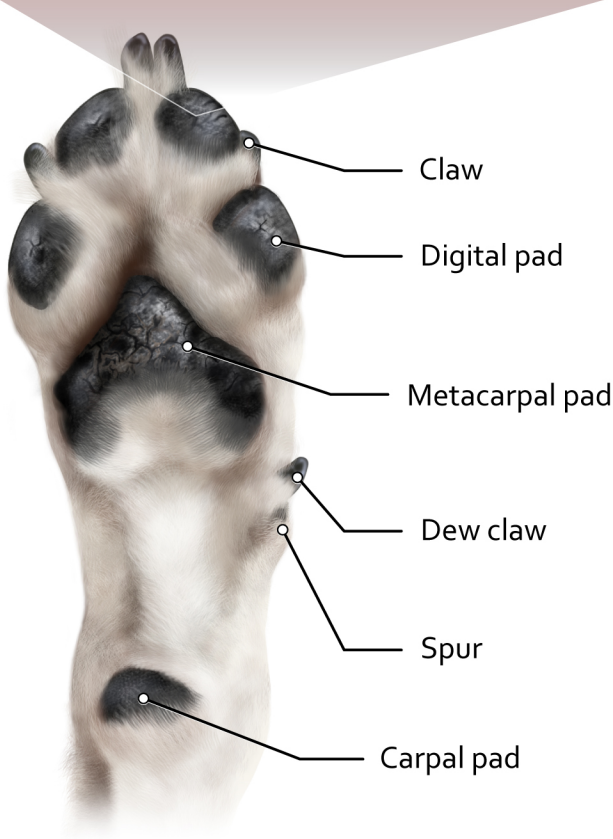Basement membrane

Dermis

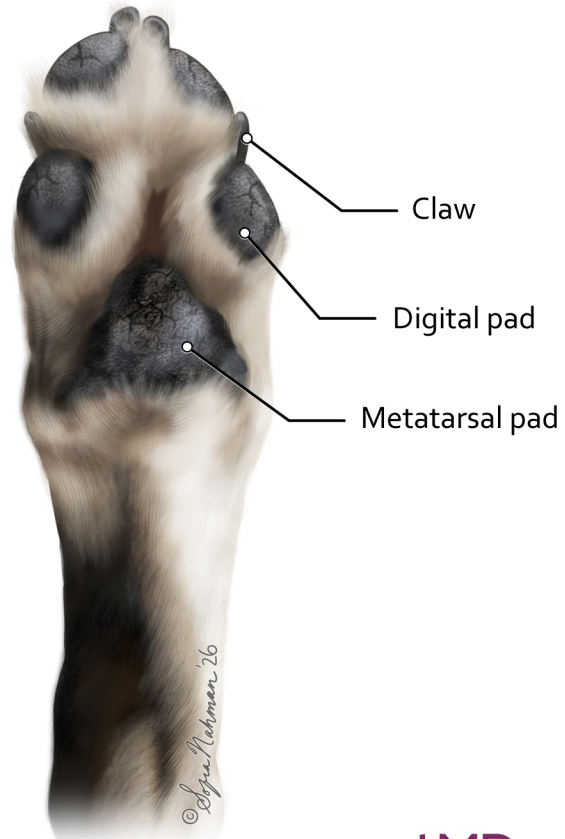
Epidermis



Anatomy of the Dog Paw



Forefoot



Hindfoot